

ORIGINAL ARTICLE

# The Double “C” Plication Technique: A Reliable Technique for Lower Facial Rejuvenation: Review of 1500 Cases

Kevin Sadati, DO, FAACS; Anthony C. Corrado, DO

**Introduction:** Facial rejuvenation procedures have evolved significantly since they were first performed at the beginning of the 20th century. Modern SMAS lifting techniques focus on providing natural facial rejuvenation, durable results, fewer complications, and reduced morbidity. Many techniques exist, each proposing different methods to attain a common goal, resuspension of the SMAS. A simple new technique for SMAS plication of lower face and neck is introduced, called double “C” plication. This technique is reproducible and simple, creating lasting results for a natural look with a low complication rate.

**Materials and Methods:** In over 1500 face-lifts in the last 4 years, the author has evolved a simple technique with a natural look. All cases were done with oral sedation and local anesthesia. Patients were ambulatory immediately following surgery and had a rapid recovery with little edema or ecchymosis. Nerve injuries were avoided, and the temple hairline and earlobe clefts were preserved. There are no ridges, dimples, or “joker lines.” Revision rate was less than 0.7%. This technique utilizes double running plication sutures in a “C” shape pattern for SMAS suspension, which can be placed via traditional or short-scar face-lift incisions. This technique provides an evenly distributed multi vector radial traction on the SMAS and lateral platysma, allowing for a more uniform suspension compared to traditional single plication and purse string sutures, which provide point specific tension. This SMAS plication technique tightens up

the face just like lacing a shoe, making the entire lower face firm and youthful. The neck plication pulls the platysma up behind the ear to maintain the earlobe up in its normal anatomical position.

**Results:** Over a 4-year period, 1532 procedures were performed utilizing the aforementioned double “C” lift technique with average follow-up of 18 months. This is a retrospective chart review of a single surgeon’s rhytidectomy practice. Of the 1532 patients, 110 had undergone previous rhytidectomy by a different surgeon. Complications included in the evaluation process were major hematoma 1.3%, minor hematoma 5%, infection 0.5%, facial nerve injury 0%, greater auricular nerve injury 0.1%, post auricular skin necrosis (>2 cm) 0.8%, and revision rate 0.7%.

**Conclusions:** The double “C” plication technique is a reliable, simple, and reproducible technique with natural results and low complications. This technique involves a double running plication suturing of SMAS and lateral platysma in a “C” shape pattern.

Lower facial rejuvenation procedures have evolved significantly since they were first performed at the beginning of the 20th century. Early facial rejuvenation techniques were based on skin excision and limited superficial skin flaps. The first major breakthrough was provided by Tord Skoog when he described his technique of dissecting beneath the superficial fascia of the face and neck in 1974.<sup>1</sup> Over the following 30 years considerable attention has been given to the superficial musculoaponeurotic system (SMAS) in the literature. Modern SMAS lifting techniques focus on providing natural facial rejuvenation, durable results, fewer complications, and reduced morbidity. These goals have been addressed using multiple methods with varying results. Many techniques exist, each proposing different methods to attain a common goal, resuspension of the SMAS.

Received for publication August 8, 2010.

From the Gallery of Cosmetic Surgery, Newport Beach, Calif (Dr Sadati) and the Newport Beach Center for Surgery, Newport Beach, Calif (Dr Corrado).

The Double “C” Plication technique in this study has been performed at multiple practices where I, Kevin S. Sadati, the senior author have been employed. I developed this technique in 2005 in my private practice. In 2007 I was hired by Lifestyle Lift™ to perform lower facial rejuvenation. I had utilized this technique on some of their patients as well. I did not receive any financial contribution for publishing this paper from any organization.

Corresponding author: Kevin Sadati, DO, FAACS, 400 Newport Center Dr, Suite 100, Newport Beach, CA 92660 (e-mail: ksadati@yahoo.com or ksadati@gmail.com).

In regard to SMAS plication, a wide array of techniques are currently available to surgeons, creating significant debate among surgeons as to the optimal technique for each patient. After considering all the novel SMAS plication techniques, the senior author (K.S.) has formulated a technique for lower facial rejuvenation which incorporates many of the superior modalities discussed in prior publications. The technique has been performed on 1532 patients over a 4-year period between 2005 and 2009 with an average of 18 months of follow-up. Due to the large patient population, the authors have been able to carefully study many aspects of the procedure with great scrutiny. After reviewing the data from this large patient cohort, the authors feel this technique provides an extremely reliable means of facial rejuvenation with limited complications. The authors present the double "C" plication technique for lower facial rejuvenation. This technique utilizes running mattress and running interlocking suturing in a double "C" shape pattern for SMAS plication, which can be placed via traditional or short-scar face-lift incisions. This technique provides an evenly distributed radial traction on the SMAS and lateral platysma, allowing for a more uniform suspension compared to traditional single interrupted plication sutures, which only provide point-specific tension. This technique has afforded the authors a strong, reliable technique that produces natural-appearing results for lower facial rejuvenation with 0.7% revision rate.

## Methods

### *Indications for a Double "C" Plication Technique*

This technique can be utilized in any patient seeking correction of generalized lower face and neck laxity (Baker type I–IV).<sup>2</sup> The Baker types are described as follows:

- Baker type I: Patients in their early to late 40s with aging primarily in the face, early jowls, and often submental fat, slight cervical skin laxity but good elasticity.
- Baker type II: Patients in their late 40s to late 50s with moderate jowls and moderate cervical skin laxity. Submental and submandibular fat are usually present, and they may have microgenia.
- Baker type III: Patients usually in their late 50s, 60s, or early 70s. They have significant jowls, moderate cervical laxity, and submental and submandibular fat. They may have significant medial platysma bands active on natural animation.

- Baker type IV: Patients usually in their 60s and 70s with significant jowls and active lax platysma bands. Cervical skin elasticity is poor, and skin folds and deep creases below the cricoid are often present.

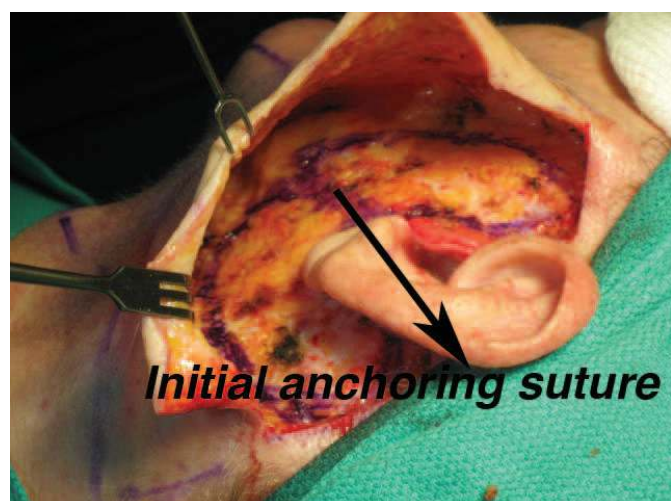
### *Technique*

After obtaining consent, diazepam, 15 mg, and diphenhydramine, 25 mg, are administered orally. Then the incision lines, extent of flap undermining, level of the mandible, pertinent neck anatomy, areas of lipodystrophy, and platysmal bands (if present) are all marked in the upright position. In the operative suite the marked area for flap elevation and liposuction is injected with warmed dilute local anesthesia (70 mL of 0.3% Xylocaine with 1:300 000 epinephrine mixed with 7 mL of sodium bicarbonate) using a 27-gauge needle. In addition, 30 mL of bupivacaine hydrochloride tumescent solution (9 mL of 0.25% bupivacaine hydrochloride with epinephrine 1:200 000 mixed with 21 mL of normal saline) was infiltrated to the marked area using a 22-gauge spinal needle. This allows a superior intraoperative hemostasis, quick flap elevation with prolonged postoperative anesthesia, and comfort.

The patient is then prepped and draped in a usual sterile fashion. Rejuvenation of the neck is completed first, if indicated. Lipocontouring of the submental area is performed with 2.0-mm and 3.7-mm single hole flat cannulae. If indicated, platysmaplasty is performed using 3.0 Vicryl in a running locking mattress suturing.

A traditional face-lift incision or short-scar incision may be utilized by the operating surgeon. The authors utilize an infratemporal hair-sparing incision which can be extended into the pre or post tragal areas. The incision is then carried around the lobule up the post-auricular sulcus just slightly on the posterior skin of the conchal bowl, to a point just even with the root of the auricular helix. The incision is then carried horizontally to the occipital hair-bearing scalp where it can be carried down along the occipital hair line. The authors feel that this incision camouflages well at the occipital hairline and prevents step-off deformities, while allowing satisfactory access to the lateral platysma.

Skin flaps are then elevated in the subcutaneous plane with a scalpel and Gorney face-lift scissors. The anterior undermining is carried out to a vertical line dropped down from the lateral canthus. Inferior undermining extends along the jowl. In Baker type III and



**Figure 1.** (Intraoperative view) Initial anchoring suture is marked from the angle of the mandible to the lobule. A “C” pattern is marked along the SMAS, anteriorly and mastoid fascia, posteriorly.

IV patients the anterior neck and lateral facial pockets are connected to allow satisfactory redraping of the neck and facial skin. Hemostasis is achieved with electrocautery.

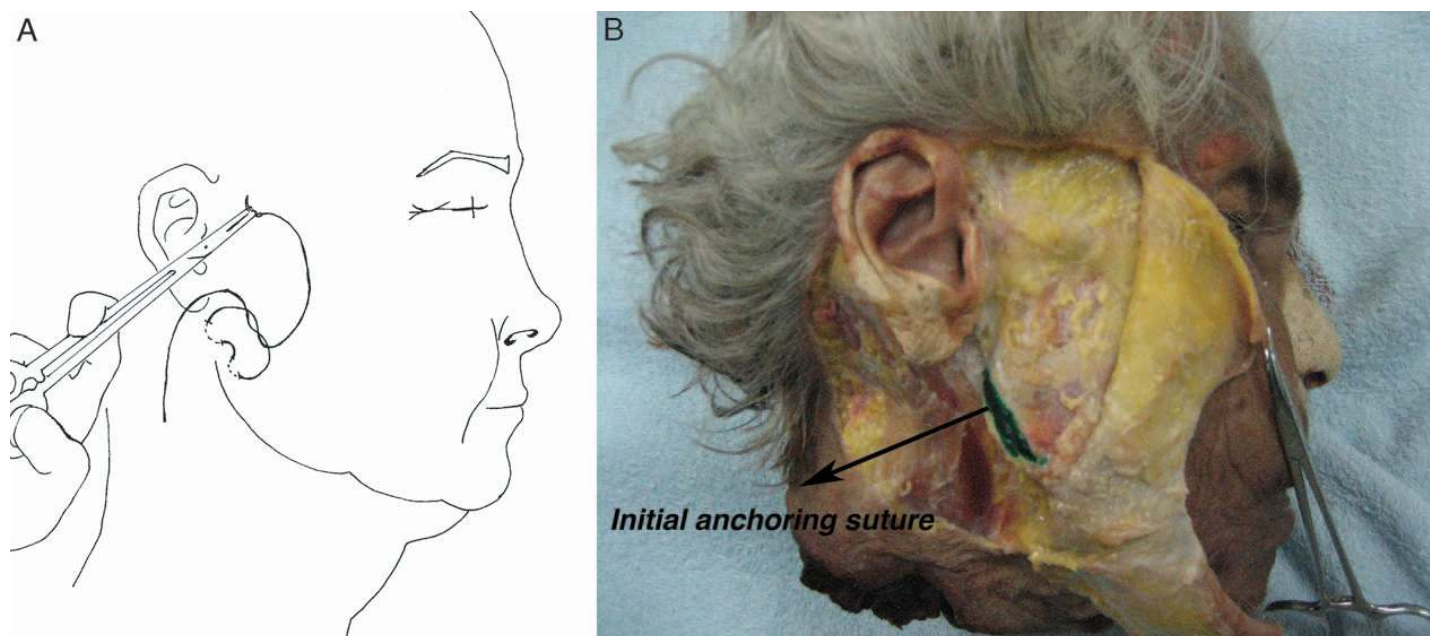
A sterile marking pen is then utilized to mark the SMAS at the level of the angle of the mandible. This is the site of our “keystone” anchoring suture. A “C” pattern is then marked on the periauricular SMAS extending inferiorly along the platysma up to the mastoid area (Figure 1).

SMAS plication starts with an initial anchoring suture at 45° along the previously marked area, utilizing a 2.0 Vicryl suture (Figure 2).

The free end of the suture is then kept long to facilitate future knot tying. Running horizontal mattress sutures are placed toward the zygoma along the marked area. The angle of plication is decreased from 45° while moving superiorly, and near the tragal area it is at 0°, whereas at the temporal region or at the top of “C” vector of plication is superior-to-inferior direction. These transitional changes in vector allow a more natural-appearing lower face and also prevents bunching of tissue and exacerbation of crow’s feet at the top (Figure 3).

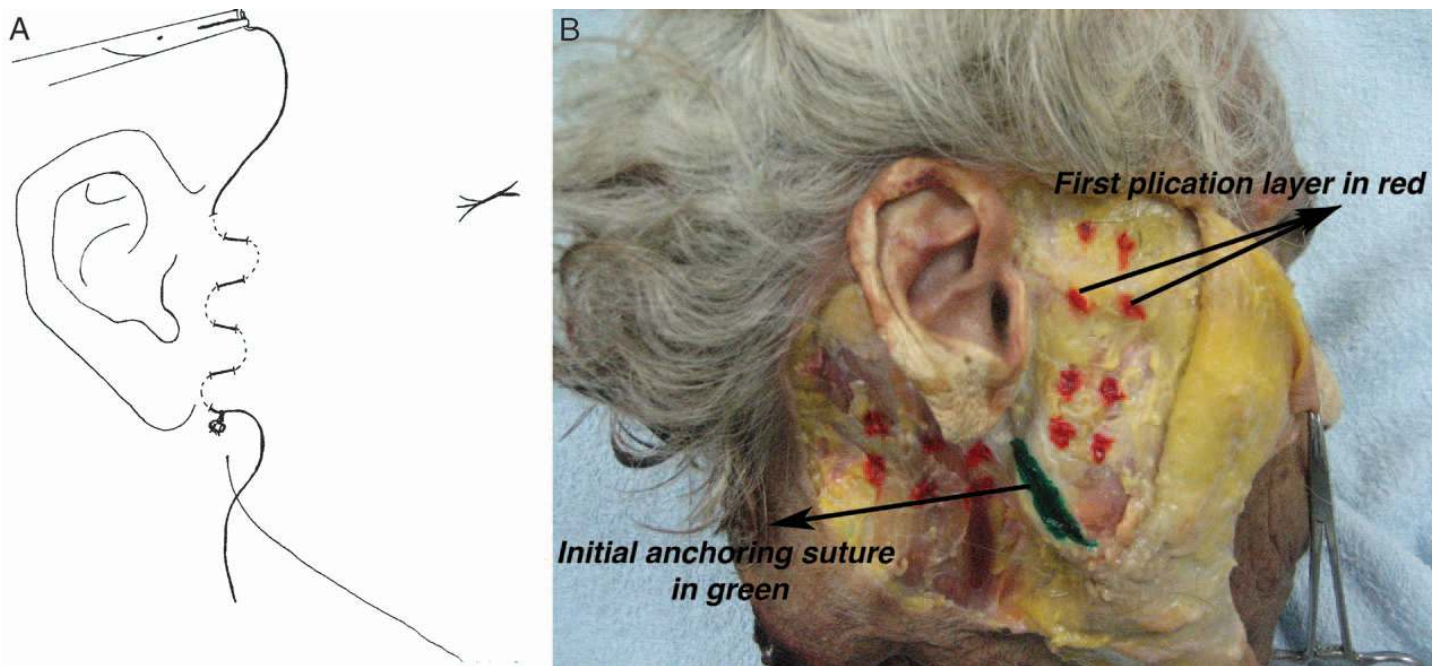
At this point the first layer of plication is completed. The second layer starts by descending running interlocking mattress suturing toward the initial anchoring suture with the same vectors. These sutures are placed outside the limits of the previous running horizontal mattress sutures, providing more strength, which also flattens any SMAS bunching encountered with the first stitch line. Once the initial anchoring suture is reached, the suture is tied to the free end and kept long again (Figures 4 and 5B).

A similar technique is used for firming the neck region. The first layer is a running horizontal mattress suture which continues along the lateral platysma up to the region of the mastoid fascia, following the curvature of the “C.” It is then followed by the second layer which is a running interlocking suture from the



**Figure 2.** (A) Illustration depicting initial anchoring suture. (B) Cadaver dissection: line initial anchoring suture is marked in green.



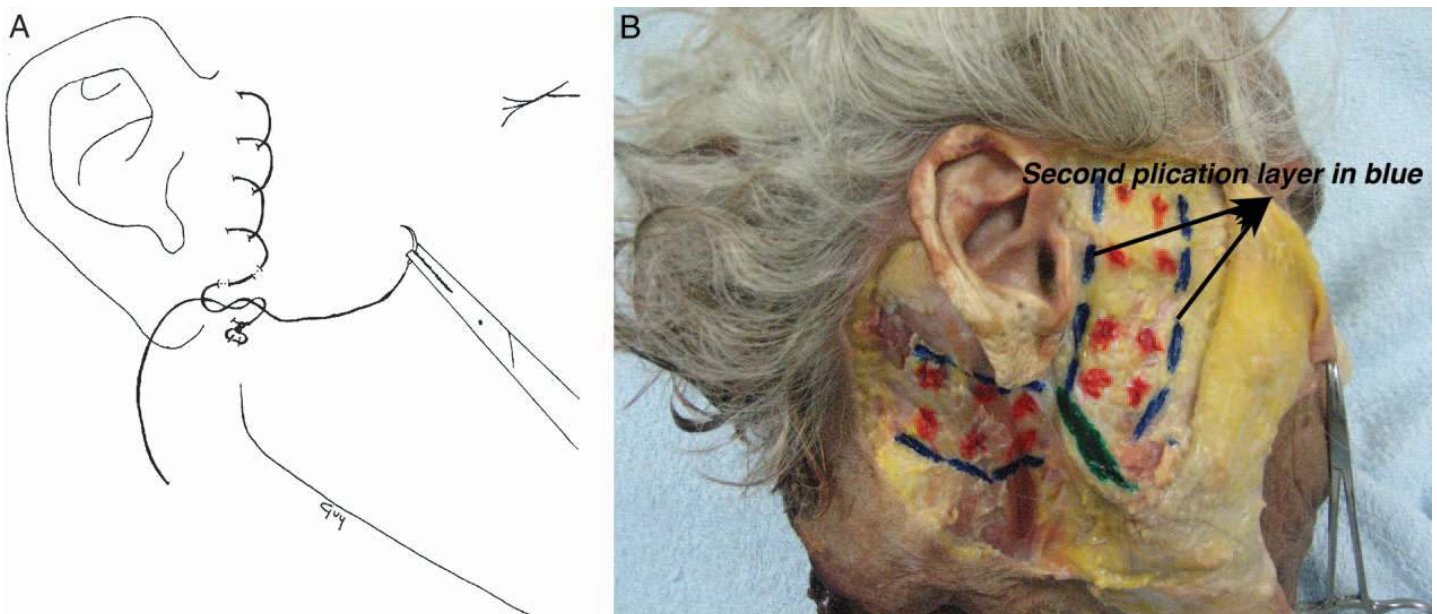


**Figure 3.** (A) Illustration of the first plication layer using a running horizontal mattress suture (facial portion). (B) Cadaver dissection: initial anchoring suture is marked in green, and the first “C” plication layer with running horizontal mattress suture is marked in red.

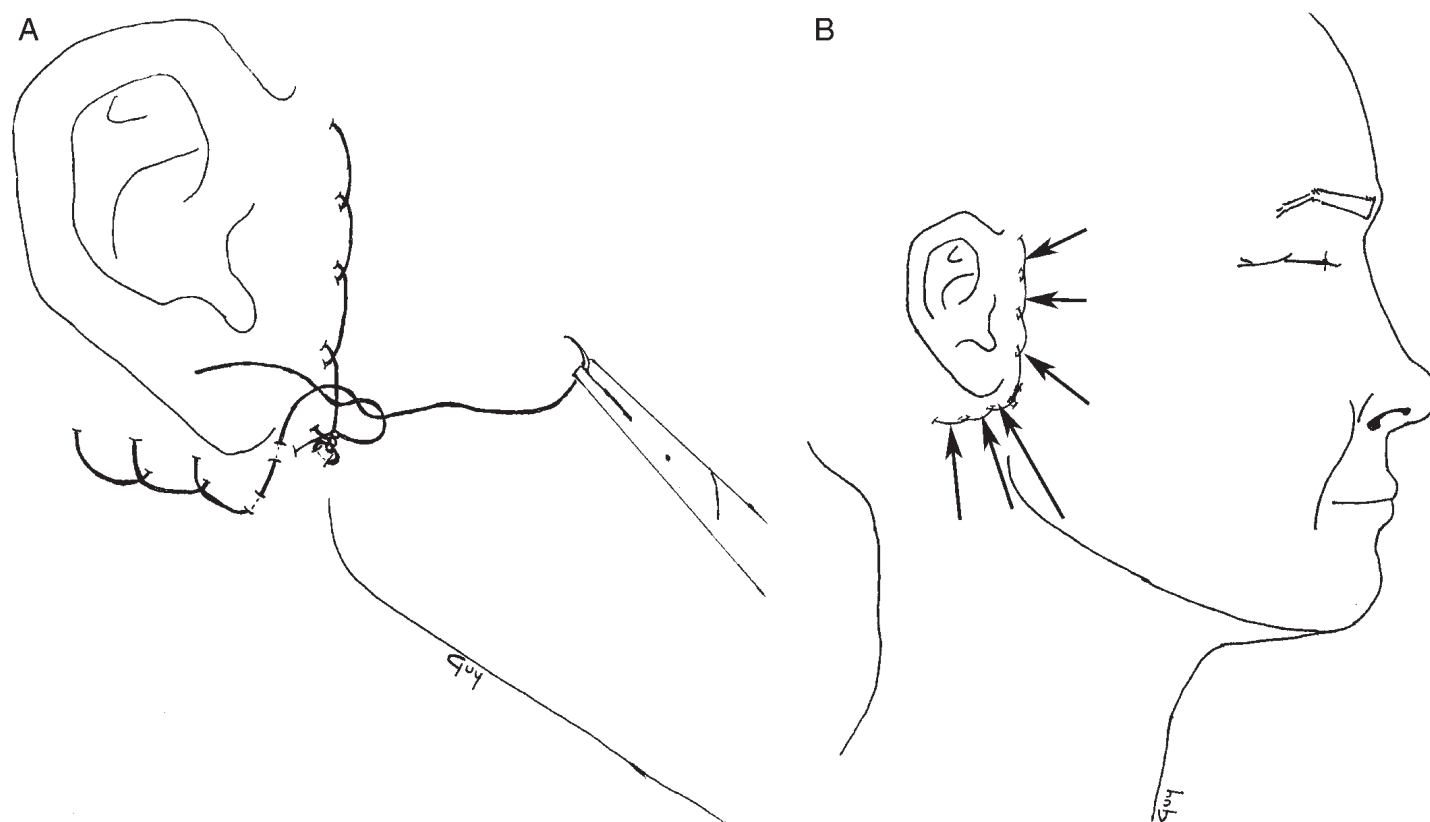
mastoid area back to the anchoring knot, where it is again tied and the ends are buried under the fat overlying the SMAS (Figure 5A).

This plication technique creates multi vector radial traction forces on the SMAS and neck tissue, therefore creating a uniform and less bunching appearance (Figure 5B).

At this point in time, the skin is then redraped, and area of excess is marked and trimmed. Most cases do not require suction drainage, but if drains are necessary, 10-mm round Jackson Pratt drains are placed under the flaps. The skin is then approximated with a few interrupted 4.0 Vicryl sutures placed in the deep dermis. The skin is closed with a 5.0 continuous



**Figure 4.** (A) Completion of second plication layer using an interlocking running mattress sutures (facial plication). (B) Cadaver dissection: second “C” plication layer with running interlocking sutures is marked in blue.



**Figure 5.** (A) Completion of the second layer of neck plication; a running interlocking suture from the mastoid area back to the anchoring knot, where it is tied again. (B) Illustration showing completion of plication and vectors of plication.

running nylon suture in the preauricular area. The postauricular area is closed with a 5.0 continuous running chromic suture. The submental incision is closed with 5.0 interrupted nylon sutures.

### Results

This study includes 1532 lower face-lift procedures over a 4-year period that were performed utilizing the aforementioned “double C” plication technique. The average age of the patient was 58 years (ranging from 38 to 86). The maximum follow-up period was 36 months and the minimum 6 months. The mean follow-up period was 18 months. This is a retrospective chart review of a single surgeon’s rhytidectomy practice. Of the 1532 patients, 1445 were women, 87 were men, and 110 had undergone previous rhytidectomy by a different surgeon. Complications included in the evaluation process were major hematoma, minor hematoma, plication suture extrusion, infection, nerve injury, postauricular skin necrosis (>2 cm), and revision rate (Table).

The senior author (K.S.) stratified the hematoma group into major and minor groups. Major hematoma is defined as postoperative active bleeding which

requires immediate wound exploration and hematoma evacuation followed by hemostasis. Minor hematoma is defined as a small pocket of blood less than 10 cm<sup>3</sup> that can be aspirated with an 18-gauge needle or expression via the incision lines. The rate of major hematoma in women was reported to be 0.9% (13/1445), while the rate in men was 8% (7/87). The total percentage of major hematoma was 2.3% (20/1532). In reviewing minor hematoma rates, the rate for women was 4.6% (67/1445), and the rate for men was 13.7% (12/87). Total minor hematoma rate was 5% (79/1532). Suture extrusion rates were analyzed, with results showing much higher rates of suture extrusion in the permanent versus absorbable suture categories. The Mersilene extrusion rate in the initial 614 patients was 1.9% (12/614), with women displaying a 1.9% extrusion rate and men a 3% extrusion rate. Utilizing Vicryl suture, the extrusion rate was 0% for the subsequent 918 cases. The overall rate of infection was 0.5%. Greater auricular nerve injury rate was studied and shown to be 0.1% overall, while facial nerve injury rate was 0% overall. Postauricular necrosis rate was 0.8% overall. Lastly, revision rates were evaluated. Revisional surgery was defined as

---



---

**List of Complications Associated With the Double “C” Plication Technique\***


---



---

Complications	Female	Male	Average of Total
Major hematoma	0.9% (13/1445)	8% (7/87)	1.3% (20/1532)
Minor hematoma	4.6% (67/1445)	13.7% (12/87)	5% (79/1532)
Mersilene extrusion	1.9% (11/581)	3% (1/33)	1.9% (12/614)
Vicryl extrusion	0% (0/864)	0% (0/54)	0% (0/918)
Infection	0.5% (7/1445)	1% (1/87)	0.5% (8/1532)
Major revision	0.7% (10/1445)	1% (1/87)	0.7% (11/1532)
Facial nerve injury	0% (0/1445)	0% (0/87)	0% (0/1532)
Greater auricular injury	0.1% (2/1445)	0% (0/87)	0.1% (2/1532)
Skin necrosis >2 cm	0.8% (12/1445)	0% (0/87)	0.8% (12/1532)
Major revision	0.7% (10/1445)	1% (1/87)	0.7% (11/1532)

\*Double “C” lift complications for 1532 patients (female = 1445, male = 87). Patients with Mersilene suture = 614; patients with Vicryl suture = 918.

major revisional surgery warranting a secondary face-lift due to a previous hematoma or an unsatisfied patient with the result within the initial 18-month follow-up period. The overall revision rate for this technique was 0.7%.

### Discussion

Much debate exists among facial plastic surgeons regarding rhytidectomy techniques. The literature is inundated with multiple techniques, with each author providing insight into which techniques he or she feels provides the greatest degree of facial rejuvenation. The face-lift surgeon must realize that each patient presents a different challenge; therefore, the surgeon must possess a vast armamentarium of facial rejuvenation procedures in order to have consistent success. The double “C” plication technique can be used in any patient seeking correction of generalized lower face and neck laxity (Baker type I–IV).<sup>2</sup>

After reviewing the plastic surgery literature, the authors set forth to define four qualities which they found to be paramount in choosing a technique for lower facial rejuvenation.<sup>3–7</sup> The four qualities of a favorable technique include procedure reliability and reproducibility, ease of learning, short operative time, and safety of technique. It is felt that the double “C” plication technique embodies all of these qualities. It provides the surgeon a reliable and reproducible technique for facial rejuvenation in a variety of patients. The technique provides a natural and lasting rejuvenation, without the suggestion of an “over pulled” look. The integral part of this technique lies in the configuration of the plication suture. By using a running plication suture in a double “C” fashion, a

multi vector radial traction force is placed on the SMAS and platysma. This SMAS plication laces the face up just like a shoe is laced, making the entire lower face tight and rejuvenated. The neck plication pulls the tissues up behind the ear, keeping the earlobe up in its normal position.

White et al<sup>8</sup> performed a biomechanical study comparing properties of two different suturing techniques for SMAS plications during rhytidectomy: a double-layered running locking (DRL) stitch and multiple interrupted horizontal mattress stitches. The DRL stitch required more force than the interrupted horizontal mattress stitch to cause significant failure of tissue plication.<sup>8</sup> They concluded that this technique may enable plastic surgeons to avoid early revision rhytidectomy due to suture failure and to create a long-lasting, youthful cosmetic result. The double “C” plication technique like DRL incorporates two layers of running plication, which in theory will afford even greater strength and reliability in SMAS suspension. The authors feel that from the biomechanical implications of the above work, and through their own investigations and patient satisfaction, this plication technique provides superior benefits in maintaining prolonged rhytidectomy results.

By allowing dissection to be limited to the subcutaneous planes, the procedure allows the novice rhytidectomy surgeon a safe and easily mastered technique for facial rejuvenation. It should be noted, that a thorough understanding of all head and neck anatomy is paramount prior to attempting any rhytidectomy technique. By maintaining a subcutaneous dissection plane, the facial nerve is placed at low risk. The reported facial nerve injury rate was 0% in 1532 patients. Careful attention is placed when dissecting

medially in the face, as well as along the mandible, to prevent inadvertent nerve injury. Care is also taken dissecting along the sternocleidomastoid muscle to prevent injury to the greater auricular nerve along its posterior border. The entire case can be performed under local anesthesia, allowing the surgeon much latitude with regard to patient desires, operative time, and operative costs.

#### Acknowledgment

The authors credit Charles W. Guy, DO for drawing the illustrations.

#### References

1. Skoog T. *Plastic Surgery: New Methods and Refinements*. Philadelphia, Pa: Saunders; 1974.
2. Baker CD. Minimal incision rhytidectomy (short scar face lift) with lateral SMASectomy: evolution and application. *Aesthet Surg J*. 2001;21:14–26.
3. Saylan Z. The S-lift for facial rejuvenation. *Int J Cosmet Surg*. 1999;7:18–23.
4. Tonnard PL, Verpaele A, Monstrey S, et al. Minimal access cranial suspension lift: a modified S-lift. *Plast Reconstr Surg*. 2002;109:2074–2086.
5. Tonnard PL, Verpaele A, Gaia S. Optimising results from minimal access cranial suspension lifting (MACS-lift). *Aesthetic Plast Surg*. 2005; 29:213–220; discussion 221.
6. Tanna N, Lindsey W. Review of 1,000 consecutive short-scar rhytidectomies. *Dermatol Surg*. 2008;34:196–203.
7. Matarasso A. National plastic surgery survey: facelift techniques and complications. *Plast Reconstr Surg*. 2000;106:1185–1195.
8. White J, Barraja M, Mengesha T, et al. Avoiding early revision rhytidectomy: a biomechanical comparison of tissue plication suture techniques. *Laryngoscope*. 2008;118:2107–2110.